10th February 2008,

Re: Comments for National Coverage Analysis (NCA) title: **Thermal Intradiscal Therapy;** CAG#: **CAG-00387N**- National Coverage Determination (NCD) Public Comment Period

Dear Sir,

I am an interventional pain physician who works in Northern Ireland, UK and has been using minimally invasive disc targeted procedures since 2001. I have used biacuplasty extensively for treatment of discogenic back pain originating from the lumbar spine. In my practice I have used several modalities to treat this type of back pain. These include IDET, Coablation and most recently Biacuplasty. Of all three therapies I have found biacuplasty to be the simplest and most easy to perform. This of course means that the procedure is less stressful for the patient as it is inherently simple (with correct technique and experience) to place two electrodes into either side of the annulus of the disc and direct a bipolar cooled RF current across them for a short time period. This produces disc heating and thermocoagulation of nerve endings in the injured annulus.

In my experience using biacuplasty for proven discogenic pain, the best results are obtained for single level posterior annular tears. Unlike some of the alternative procedures such as IDET or disctrode, where the annulus is traversed by an electrode, with the possibility of further fissures being created by the treatment process, this is avoided by the gentler biacuplasty procedure. Certainly one is impressed by the fact that those patients having biacuplasty have much less procedure associated pain and also less post operative pain than those having the other two procedures.

What is the alternative for these patients disabled with chronic low back pain? Surgery is best avoided for this pathology, and the conservative options of non interventions are also not helpful for many. This type of minimally invasive disc targeted procedure offers such properly selected patients the chance of long term pain relief and subsequent improvement in their activities of daily living.

In my opinion disc targeted procedures are minimally invasive, with low risk and low morbidity.

My patients are grateful for such minimally invasive disc targeted procedures and I would respectfully suggest that these procedures continue to be available for North American patients.

Yours sincerely,

Dr AR Cooper MD FIPP

OCONNOR, DEIRDRE E. (CMS/OCSQ)

From: Farshad Ahadian [fahadian@ucsd.edu]
Sent: Wednesday, January 23, 2008 6:58 PM
To: OCONNOR, DEIRDRE E. (CMS/OCSQ)
Subject: IDET

Dear Ms. Oconnor, I am an Associate Clinical Professor of Anesthesiology and the Medical director for the Center for Pain Medicine at University of California. I have extensive experience in
treatment of spine and disc problems. I have studied the efficacy
and safety of electrothermal disc decompression at our institution.
A couple of abstracts were presented at the AAPM and ASRA annual meeting back in 2004 and 2005 and should be available for your review on line if you wish. I have also reviewed cases regarding adverse events from this therapy. Overall this can be a very effective, safe and economical treatment for a select population of patients with back pain. It is unfortunate that the misuse of the procedure in the past by worker's comp providers resulted in a bad reputation. Proper patient selection is important in achieving good success. I am happy to provide you with further information if necessary. However, I do support adding this treatment to your covered benefits.

Kindest regards,
Farshad Ahadian, M.D.
Associate Clinical Professor of Anesthesiology Medical Director, Center for Pain Medicine
University of California, San Diego

Baylis MEDICAL

February 12, 2008

Deirdre O'Connor
Jyme Schafer, M.D., M.P.H.
Centers for Medicare and Medicaid Services
Coverage and Analysis Group
Mail Stop C1-09-06
7500 Security Boulevard
Baltimore, MD 21244-1850

RE: CAG-00387N:
Comment on Proposed Coverage For Thermal Intradiscal Therapy

Dear Ms. O'Connor and Dr. Schafer:

On behalf of Baylis Medical Company, I am pleased to submit the enclosed dossier in support of expanding Medicare coverage to include thermal intradiscal therapy as a minimally invasive treatment for patients with chronic low back pain originating in the lumbar or sacral discs.

At the present time, individuals with chronic low back pain have two difficult and costly options available to them: spinal fusion surgery, or prolonged medical management with narcotics. As explained in more detail in the dossier included in Appendix B, disc biacuplasty offers a safe and effective treatment for chronic low back pain that ablates the affected nerve endings in the posterior annulus and remodels collagen fibers. This procedure does not require a lengthy inpatient admission or indefinite pain management protocols. It can be performed by a trained pain management physician at a fraction of the cost of either invasive surgery or long-term narcotic treatment. To date, the research shows that disc biacuplasty consistently results in significant pain relief and functional improvement using multiple outcome tools, with far less risk of a serious adverse event. The Temperature Mapping Studies provided in Appendix C explain the mechanisms of action of Thermal Disc Treatment.

A Local Coverage Determination (LCD) for Thermal Intradiscal Therapy has been issued by Pinnacle Business Solutions, a CMS Contracted Intermediary and Carrier for Arkansas and Rhode Island. This allows coverage of the Thermal Intradiscal therapies for the patient population that meets with specific selection criteria. We would like to propose some minor revisions to this LCD and request this revised Local Coverage Determination to be considered for being adopted as

Baylis Medical Company Inc.
2645 Matheson Blvd. East, Mississauga ON Canada L4W 5S4 / Tel.: (905) 602-4875 / Fax: (905) 602-5671
www.baylismedical.com

the National Coverage Determination for Thermal Intradiscal Therapy. The LCD with the proposed changes is included in Appendix A of this submission.

We appreciate CMS's interest in making disc biacuplasty available to Medicare beneficiaries. Since this is CMS's initial consideration of the evidence, we believe that it would be helpful both for CMS and Baylis Medical to meet once the comment period closes and the CAG staff has reviewed the submissions. We propose that at the meeting, CAG's staff can meet with pain management physicians familiar with disc biacuplasty, who can explain the procedure from their perspective and answer questions that the CAG staff may have. We would be happy to schedule this meeting at your convenience.

In the interim, please contact me at (905) 602-4875; ext 222 if you have any questions concerning the enclosed materials.

Sincerely,

Kris Shah
Vice President

Enclosure:

Appendix A: Pinnacle Local Coverage Determination for Thermal Intradiscal Therapy with Proposed Revisions

Appendix B: Disc Biacuplasty – Clinical Review

Appendix C: Temperature Mapping Studies

References

Baylis Medical Company Inc.
2645 Matheson Blvd. East, Mississauga ON Canada L4W 5S4 / Tel.: (905) 602-4875 / Fax: (905) 602-5671
www.baylismedical.com

OCONNOR, DEIRDRE E. (CMS/OCSQ)

From: CMS CAGInquiries
Sent: Thursday, February 14, 2008 10:01 AM
To: OCONNOR, DEIRDRE E. (CMS/OCSQ)
Subject: FW: Biacuplasty

From: robert hein [mailto:rmhhein@yahoo.com]
Sent: Wednesday, February 13, 2008 9:46 PM
To: CMS CAGInquiries
Subject: Biacuplasty

Thermal Intradiscal Therapy

CAG-00387N

My name is Robert Hein. I am a pain fellow who has been to a formal biacuplasty course as part of my training. As one who provides interventional pain management, thermal intradiscal therapy provides patients a real treatment option that alleviates pain and does so in a minimally invasive fashion. Disc related pain is a very real entity that I see routinely. Being able to heat it in order to stop any further degeneration or to seal up any tears or leaks is a remarkable tool to be able to provide patients. I strongly urge you to consider thermal intradiscal therapy a valid treatment tool in the management of back pain. As an added feature it is one of very few options that are available in medicine that allows a patient to "try it out" first, since we only offer it to properly selected pt's after they have had a positive discogram specifically identifying the pain generating disc.

Looking for last minute shopping deals? Find them fast with Yahoo! Search.

Customer **02/14/2008 12:40 PM**

Referring URL:

I have used the procedure in my practice. Although I am relatively new to the procedure and I dont have much solid patient feed back. I feel it should be added just due to the fact that treat isolated axial back pain is difficult. This procedure is one of the few interventional treatments available to help this population of patients.

fuss5@hotmail.com

Customer **02/14/2008 07:01 PM**

IDET is a good procedure for pts who did not respond to conventional injection procedures and who are not candidates for surgery. Presently there is a large group of these pts gathered in many pain management clinics. They suffer from chronic pain and could only take pain meds.IDET would offer hope to some of these pts. To answer some of the criticisms of IDET, it is not going to be effective in a high percentage of pts, but even a small percentage would make a big difference in quality of life.
jddai@attglobal.net

Customer **02/07/2008 12:53 PM**

I am asking that the "IDET" Prcedure be a covered benefit for Medicare patients. The IDET procedure helps decrease pain by cauterizing nerves as well as helps stabilize the spine. The cost is 1/10 of a similar fusion and outcomes are nearly the same. The procedure could be done in an office based setting that would limit the cost to 1/2 of the hopsital setting, nettinga a savings for medicare up to 3000%!
edwash@comcast.net

attached to comment

FSIPP

Florida Society of Interventional Pain Physicians, Inc.

PO Box 330298, Atlantic Beach FL 32233-0298
Phone: 904 270 8886, Fax: 904 246 9233
Email: info@flsipp.org, http://flsipp.org

January 25, 2008

Regarding: Intradiscal Thermal Therapy

Members of the Committee for Medicare National Coverage Determination:

I am writing this response regarding the National Coverage Determination for Intradiscal Thermal Therapy. As the current president of the Florida Society of Interventional Pain Physicians (FSIPP), my response is on behalf of our entire organization. I have attached a literature review with a brief outline of each of 20 articles supporting these procedures for your review. Of course the literature contains hundreds of articles, but I find these to be well stated and from top investigators and universities in the country.

Since the first injection of chymopapain in 1963, percutaneous intradiscal therapies have evolved and been used to treat discogenic back and leg pain. These percutaneous techniques treat contained disc herniations and internal disc derangements by decompressing disc material. Mechanically removing or cauterizing small volumes of tissue from the disc nucleus and or annulus leads to a large reduction in overall disc pressure with consequent relief of neural compression. Additionally, chemically active substances released by the disc material are diminished by the cauterization process.

Although rigorous clinical testing of the efficacy of these procedures is ongoing there are scarce reports of complications. With a 40-year history confirming the concept of percutaneous disc decompression and subsequent intradiscal thermal therapy, the results are promising. Early biomechanical and histologic investigations into the effects of Intradiscal Thermal Therapy were conflicting, however the recent literature has increased the support and recognition of this modality of therapy. As with all areas of medical knowledge ongoing studies are necessary to improve the safety and efficacy of the intervention as well as expand the data. In the case of Intradiscal Thermal Therapy, however, I am confident that we have achieved sufficient data to allow coverage. To date, minimally-invasive Intradiscal Thermal Therapy has received honorable attention in the university, private sector, and with well renowned investigators in the literature (see attachment).

Low back pain (LBP) is a major physical and socioeconomic entity. A significant percentage of LBP is attributable to internal disc disruption costing individuals their livelihood and financial burdens leading to the necessity for Social Security Disability. The management of internal disc disruption has traditionally been limited to either conservative treatment or spinal fusion. In patients who are functionally disabled surgical spinal fusion offers a costly and invasive intervention with statistically significant complications.

Our organization is strongly in favor of a positive coverage determination for Intradiscal Thermal Therapy. Please feel free to contact me if you have any further questions or needs that I may address.

Sincerely,

Lora Brown, MD, ABIPP, DAPM
President, FSIPP

FSIPP
Florida Society of Interventional Pain Physicians, Inc.

PO Box 330298, Atlantic Beach FL 32233-0298
Phone: 904 270 8886, Fax: 904 246 9233
Email: info@flsipp.org, http://flsipp.org

BIBLIOGRAPHY
INTRADISCAL THERMAL THERAPY

1. Kapural L, Mekhail N. Novel intradiscal biacuplasty (IDB) for the treatment of lumbar discogenic pain, Pain Pract. 2007 Jun;7(2):130-4.

Department of Pain Management, The Cleveland Clinic Foundation, reported here the treatment of severe axial discogenic pain in a young man utilizing minimally invasive transdiscal radiofrequency technique,l biacuplasty. There were no intra- and postoperative complications, and significant improvements in patient functional capacity, and pain scores were noted.

2. Andersson GB, Mekhail NA, Block JE. Treatment of intractable discogenic low back pain. A systematic review of spinal fusion and intradiscal electrothermal therapy (IDET). Pain Physician. 2006 Jul;9(3):237-48.

Department of Orthopedic Surgery, Rush University Medical Center conducted a systematic review of clinical outcomes in patients undergoing spinal fusion or the intradiscal electrothermal therapy (IDET) procedure for intractable discogenic low back pain. They concluded that the majority of patients reported improvement in symptoms following both spinal fusion and the IDET procedure. The IDET procedure appears to offer sufficiently similar symptom amelioration to spinal fusion without the attendant complications. Perioperative complications were commonly associated with spinal fusion (median: 14%, range: 2% to 54%, n = 31 study groups) whereas adverse events were rarely experienced with the IDET procedure (median: 0%, range: 0% to 16%, n = 14 studies).

3. Deen HG, Fenton DS, Lamer TJ. Minimally invasive procedures for disorders of the lumbar spine. Mayo Clin Proc. 2003 Oct;78(10):1249-56.

Department of Neurosurgery , Mayo Clinic, Jacksonville, Fla Percutaneous lumbar diskectomy techniques hold considerable promise; however, lumbar microdiskectomy is the gold standard for surgical treatment of lumbar disk protrusion with radiculopathy Intradiskal electrothermal therapy is emerging as a useful option for selected patients with intractable mechanical back pain whose only other option historically has been a spinal fusion.

4. Derby R, Baker RM, Lee CH, Anderson PA. Evidence-informed maanagement of chronic low back pain with intradiscal electrothermal therapy. Spine J. 2008 Jan-Feb;8(1):80-95

5. Malik K, Joseph NJ. Intervertebral disc a source of pain? Low back pain: problems and future directions--case reports. Middle East J Anesthesiol. 2007 Oct;19(3):683-92.

Department of Anesthesiology, Illinois Masonic Medical Center provides arguments that link discal therapy to resolution of patients' symptoms and evidence supporting the idea that intervertebral disc is a source of low back pain. New treatment modalities are becoming available which if applied early may stop disc disruption. Without diagnosis and treatment, disc disruption evolves to advanced stages of spinal dysfunction. Intervertebral disc is a source of low back pain that is often ignored. Early diagnosis and treatment of a painful disc may reduce enormous pain and suffering from low back pain.

6. Cohen SP, Shockey SM, Carragee EJ. The efficacy of repeat intradiscal electrothermal therapy. Anesth Analg. 2007 Aug;105(2):495-8.

Pain Management Division, Department of Anesthesiology and Critical Care Medicine, Johns Hopkins School of Medicine. Nine consecutive patients with discogenic low back pain who obtained excellent pain relief from intradiscal electrothermal therapy were treated with a repeat procedure after the beneficial effects had diminished. Although 4 of 9 patients obtained > or =50% pain relief and were satisfied with the results, both the degree and duration of benefit were less pronounced than after the first procedure.

7. Malik K. Treatment of multilevel degenerative disc disease with intradiscal electrothermal therapy. Anaesth Intensive Care. 2007 Apr;35(2):289-93.

Department of Anesthesiology, Illinois Masonic Medical Center reports indicate that intradiscal electrothermal therapy can be performed at multiple levels at a single sitting, compared to intradiscal electrothermal therapy performed at one to two discs at a time, this approach may obviate the need for surgery and may reduce the duration of pain and disability incurred.

8. Freeman BJ. IDET: a critical appraisal of the evidence. Eur Spine J. 2006 Aug;15 Suppl 3:S448-57. Epub 2006 Jul 26.

Centre for Spinal Studies and Surgery, Queen's Medical Centre, University Hospital, Nottingham, UK. Review that Smith and Nephew (Endoscopy division, Andover, MA, USA) have estimated that 60,000 Intra-Discal Electrothermal Therapy (IDET) procedures have been performed world wide up to June 2005. This paper reviews the current evidence of clinical efficacy for IDET obtained via a systematic review of the literature. The evidence for efficacy of IDET remains weak and has not passed the standard of scientific proof. The evidence for efficacy of IDET remains weak and has not passed the standard of scientific proof.

9. Appleby D, Andersson G, Totta M. Meta-analysis of the efficacy and safety of intradiscal electrothermal therapy (IDET). Pain Med. 2006 Jul-Aug;7(4):308-16.

The objective of this study was to determine the representative outcomes of the intradiscal electrothermal therapy (IDET) procedure in terms of pain relief, reduction of disability, and risk of complications by Meta-analysis, using a random-effects model. A Medline literature search was conducted using search terms associated with the IDET procedure including IDET, intradiscal electrothermal therapy, intervertebral disk, and annuloplasty. The overall incidence of complications was 0.8%. Although variation exists in the reported outcomes among the various studies of the IDET procedure, the pooled results of the published studies provide compelling evidence of the relative efficacy and safety of the IDET procedure.

10. Andersson GB, Mekhail NA, Block JE. Treatment of intractable discogenic low back pain. A systematic review of spinal fusion and intradiscal electrothermal therapy (IDET). Pain Physician. 2006 Jul;9(3):237-48.

Department of Orthopedic Surgery, Rush University Medical Center conducted a systematic review of clinical outcomes in patients undergoing spinal fusion or the intradiscal electrothermal therapy (IDET) procedure for intractable discogenic low back pain. Articles were selected if disc degeneration or disruption was the primary indication for spinal fusion or the IDET procedure and if follow-up outcome data included evaluations of back pain severity, condition-specific functional impairment and/or health-related quality of life. Data were extracted and summarized on patient characteristics, surgical methods, and clinical outcomes. Overall, there were similar median percentage improvements realized after spinal fusion and the IDET procedure, respectively, for 2 of the 3 outcomes evaluated: pain severity (50%, 51%), back function (42%, 14%) and quality of life (46%, 43%). Perioperative complications were commonly associated with spinal fusion (median: 14%, range: 2% to 54%, n = 31 study groups) whereas adverse events were rarely experienced with the IDET procedure. Randomized controlled trials of spinal fusion, in particular, had important methodological limitations. The majority of patients reported improvement in symptoms following both spinal fusion and the IDET procedure. The IDET procedure appears to offer sufficiently similar symptom amelioration to spinal fusion without the attendant complications.

11. Zhou Y, Abdi S. Diagnosis and minimally invasive treatment of lumbar discogenic pain--a review of the literature. Clin J Pain. 2006 Jun;22(5):468-81.

University of Florida, Comprehensive Pain Management, Lake City reviews that the diagnosis and treatment of lumbar discogenic pain due to internal disc disruption (IDD) remains a challenge. It accounts for 39% of patients with low back pain. Provocative discography can provide unique information about the pain source and the morphology of the disc. Adjunctive therapies, including nonsteroidal anti-inflammatory drugs, physical therapy, rehabilitation, antidepressants, antiepileptics, and acupuncture, have been used for low back pain. The value of these treatments for discogenic pain is yet to be established. Intradiscal steroid injection has not been proved to provide long-term benefits. Intradiscal

electrothermal therapy may offer some pain relief for a group of well-selected patients. Minimally invasive treatments provide alternatives for discogenic pain with the appeal of cost-effectiveness and, possibly, less long-term side effects. More basic science and clinical studies are needed to improve the clinical efficacy of minimally invasive treatments.

12. Pomerantz SR, Hirsch JA. Intradiscal therapies for discogenic pain. Semin Musculoskelet Radiol. 2006 Jun;10(2):125-35.

Department of Neuroradiology, Massachusetts General Hospital, Boston concludes that discogenic low back pain can also arise from annular tears and other forms of internal disc derangement (IDD). Annuloplasty techniques, such as IntraDiscal Electrothermal Therapy (IDET) and discTRODE, have been developed over the past decade that thermally treat the lesions of IDD. Although the therapeutic mechanisms of thermal annuloplasty have yet to be fully elucidated, research studies demonstrate that the procedure can be effective for appropriately selected patients with degenerative disc disease characterized by discographically proven painful annular fissures. Other novel intradiscal therapies are emerging for percutaneous treatment of discogenic pain and await more widespread clinical evaluation.

13. Singh V, Derby R. Percutaneous lumbar disc decompression. Pain Physician. 2006 Apr;9(2):139-46.

Percutaneous techniques are rapidly replacing traditional open surgery in operations requiring discectomy, decompression, and fusion. The percutaneous access to the disc was first used in the 1950s to biopsy the disc with needles. Percutaneous access to the disc using endoscopic techniques was developed in the 1970s. The indications for percutaneous lumbar disc decompression include low back and lower extremity pain caused by a symptomatic disc. Internal disc disruptions and disc herniations are common causes of low back and/or lower extremity pain which may become chronic, if not diagnosed and treated. Annular tears lead to migration of the nuclear material and deranged internal architecture. In the chronically damaged intervertebral disc, leakage of nuclear material from annular tears can initiate, promote, and continue the inflammatory process and delay or stop recovery of vital remaining intradiscal tissue. The most often stated goal of central nuclear decompression is to lower the pressure in the nucleus and to allow room for the herniated fragment to

implode inward. Provocative discography prior to percutaneous lumbar disc decompression is recommended. Percutaneous disc decompression may result in a small number of complications but occasionally, these could be serious.

14. Fukui S. Changes on MRI in lumbar disc protrusions in two patients after intradiscal electrothermal therapy. J Anesth. 2006;20(2):132-4.

Department of Anesthesiology, Shiga University of Medical Science examined changes to the protruded lumbar disc after intradiscal electrothermal therapy (IDET) using magnetic resonance imaging (MRI) in two patients with chronic discogenic low back pain who underwent IDET. MRI was performed before and 6 months after the treatments. In the follow-up MRI studies, the protrusions were almost abolished and normalized in both patients. We thus confirmed shrinkage of the protruded disc by IDET on MRI images in two patients.

15. Rozen D, Grass GW. Intradiscal electrothermal coagulation and percutaneous neuromodulation therapy in the treatment of discogenic low back pain. Pain Pract. 2005 Sep;5(3):228-43.

Department of Anesthesiology and Pain Medicine, Mount Sinai Medical Center, New York, state that intradiscal electrothermal coagulation (IDET) and percutaneous neuromodulation therapy (PNT) are now being performed as an alternative to these surgery and conservative therapy. Early biomechanical and histologic investigations into the effects of IDET are conflicting. However, in early prospective human trials, IDET seems to provide some benefit with little risk. IDET is potentially beneficial treatment for internal disc disruption in carefully selected patients as an alternative to spinal fusion. More basic science and clinical research with long-term follow-up evaluation is necessary.

16. Singh K, Ledet E, Carl A. Intradiscal therapy: a review of current treatment modalities. Spine. 2005 Sep 1;30(17 Suppl):S20-6.

Department of Orthopedic Surgery, Rush University Medical Center, Chicago, IL, provides a systematic review of the medical literature regarding current intradiscal therapeutic methods. Current treatment of intradiscal disease is rapidly evolving and as such should be a multidisciplinary effort that follows a logical, orderly algorithm. Minimally

invasive techniques, namely, intradiscal electrothermal therapy (IDET), radiofrequency ablation (RFA), percutaneous endoscopic laser discectomy (PELD), and cryoablation have challenged the conventional surgical management of back pain. Thirty-eight research reports, published between 1986 and 2005, were systematically reviewed for disease classification, surgical intervention, and treatment outcomes. The surgical literature on the management of intradiscal disease continues to be limited to large series with short clinical follow-ups. Arthrodesis continues to be the primary treatment modality in the majority of patients. Newer treatment options including IDET, RFA, PELD, and cryoablation have shown promising results with regards to symptomatic relief and early return to function.

17. Biyani A, Andersson GB, Chaudhary H, An HS. Intradiscal electrothermal therapy: a treatment option in patients with internal disc disruption. Spine. 2003 Aug 1;28(15 Suppl):S8-14.

Department of Orthopedic Surgery, Medical College of Ohio, Toledo conducted a literature review of the anatomy, pathophysiology, diagnosis, procedure, and clinical results of intradiscal electrothermal therapy (IDET). Low back pain is a major physical and socioeconomic entity. A significant percentage of low back pain is attributable to internal disc disruption. The management of internal disc disruption has traditionally been limited to either conservative treatment or spinal fusion. IDET has been performed as an alternative to these therapies. In early prospective human trials, IDET seems to provide some benefit with little risk. and is potentially beneficial treatment for internal disc disruption in carefully selected patients as an alternative to spinal fusion. More basic science and clinical research with long-term follow-up evaluation is necessary.

18. Lutz C, Lutz GE, Cooke PM. Treatment of chronic lumbar diskogenic pain with intradiskal electrothermal therapy: a prospective outcome study. Arch Phys Med Rehabil. 2003 Jan;84(1):23-8.

Physiatry Service, Hospital for Special Surgery, New York, provides a Prospective case series to determine the clinical efficacy of intradiskal electrothermal annuloplasty in treating patients with chronic constant lumbar diskogenic pain who have not responded to at least 6 months of aggressive nonoperative care. A total of 33 patients, with mean age of 40 years and a mean duration of symptoms of 46 months, were observed with

a mean follow-up of 15 months. Complete pain relief was achieved in 24% of the patients, and partial pain relief in 46% of the patients. They concluded that intradiskal electrothermal annuloplasty offers a safe, minimally invasive treatment option for carefully selected patients with chronic lumbar diskogenic pain who have not responded to aggressive nonoperative care.

19. Wetzel FT, McNally TA. Treatment of chronic discogenic low back pain with intradiskal electrothermal therapy. J Am Acad Orthop Surg. 2003 Jan-Feb;11(1):6-11.

Section of Orthopaedic Surgery and Rehabilitation Medicine and Anesthesia and Critical Care, University of Chicago Spine Center Chicago, IL, notes that the treatment of chronic, nonradicular, discogenic low back pain remains controversial. The posterior anulus fibrosus appears to be a potential site of origin of the pain, which is mediated by nociceptors in the inner layers of the anulus. Success rates of spinal fusion range from 39% to 96%. Reported therapeutic success rates of intradiskal electrothermal therapy, a possible intermediate treatment, range from 60% to 80%.

18. O'Neill CW, Kurgansky ME, Derby R, Ryan DP. Disc stimulation and patterns of referred pain. Spine. 2002 Dec 15;27(24):2776-81.

Spinal Diagnostics and Treatment Center, Daly City, California studied a total of 25 consecutive patients meeting inclusion criteria completed a pain diagram before undergoing the intradiscal electrothermal annuloplasty procedure. The location, intensity, and familiarity of any pain provoked during disc heating were correlated with presenting symptoms and duration of heatingt o determine the pattern of pain response to noxious stimulation of the intervertebral disc. During disc heating, 68% of patients reported exact reproduction of their presenting pain, in both pain quality and location. None of the patients experienced unfamiliar pain during the procedure. The pattern of pain reproduction was consistent; pain originated proximally and progressed distally as stimulus intensity increased. Noxious stimulation of the intervertebral disc may result in low back and referred extremity in patients presenting with these symptoms. The distal extent of pain produced depends on the intensity of stimulation. Disc stimulation may reproduce pain that extends to below the knee.

19. Saal JA, Saal JS. Intradiscal electrothermal treatment for chronic discogenic low back pain: prospective outcome study with a minimum 2-year follow-up. : Spine. 2002 May 1;27(9):966-73; discussion 973-4.

SOAR, Physiatry Medical Group, Menlo Park, California, conducted a prospective longitudinal study with a minimum 2-year follow-up. To assess the long-term outcome of a group of patients with chronic discogenic low back pain who had failed to improve with comprehensive nonoperative care and who were subsequently treated with intradiscal electrothermal therapy (IDET). Bodily pain and physical function scores demonstrated significant improvement between the 1- and 2-year observation points. Additionally, quality of life improvement was demonstrated by a statistically significant improvement in all the SF-36 subscales. A cohort of patients with chronic discogenic low back pain who had failed to improve with comprehensive nonoperative care demonstrated a statistically significant improvement in pain, physical function, and quality of life at 2 years after IDET.

20. Singh V. Intradiscal electrothermal therapy: a preliminary report. Pain Physician. 2000 Oct;3(4):367-73.

Pain Diagnostic Associates, Niagara, WI.reports intradiscal electrothermal therapy has been shown to be effective in managing chronic disabling discogenic pain. This prospective pilot outcome study was designed to investigate the effectiveness of intradiscal electrothermal annuloplasty in a series of patients with chronic functionally disabling discogenic low back pain. The results showed greater than 50% pain relief in 67% of the patients. In addition, a significant decrease in visual analog pain scores was also seen. Further, the assessment of functional status showed significant improvement with standing and walking, whereas sitting also demonstrated significant improvement in 62% of the patients, though it was not statistically significant. No complications were noted in the perioperative period or during the follow-up period. In conclusion, intradiscal electrothermal therapy is a safe and effective procedure in patients suffering with chronic functionally limiting discogenic pain who fail to respond to aggressive conservative modalities of treatments as well as interventional therapy with injections.

OCONNOR, DEIRDRE E. (CMS/OCSQ)

From: CMS CAGInquiries
Sent: Tuesday, January 29, 2008 10:47 AM
To: OCONNOR, DEIRDRE E. (CMS/OCSQ)
Subject: FW: Thermal Intradiscal Therapy, CAG 00387N
Attachments: Disc Biacuplasty Clinical Review 08-Oct-2007.doc

---

From: Dr. Tracy [mailto:tracypain@tampabay.rr.com]
Sent: Monday, January 28, 2008 12:42 PM
To: CMS CAGInquiries
Subject: Thermal Intradiscal Therapy, CAG 00387N

I have submitted a comment and attached is the literature for you Medical Directors review.

Deborah H. Tracy

DISC BIACUPLASTY
Clinical Review

A new and effective option to treat intractable discogenic back pain

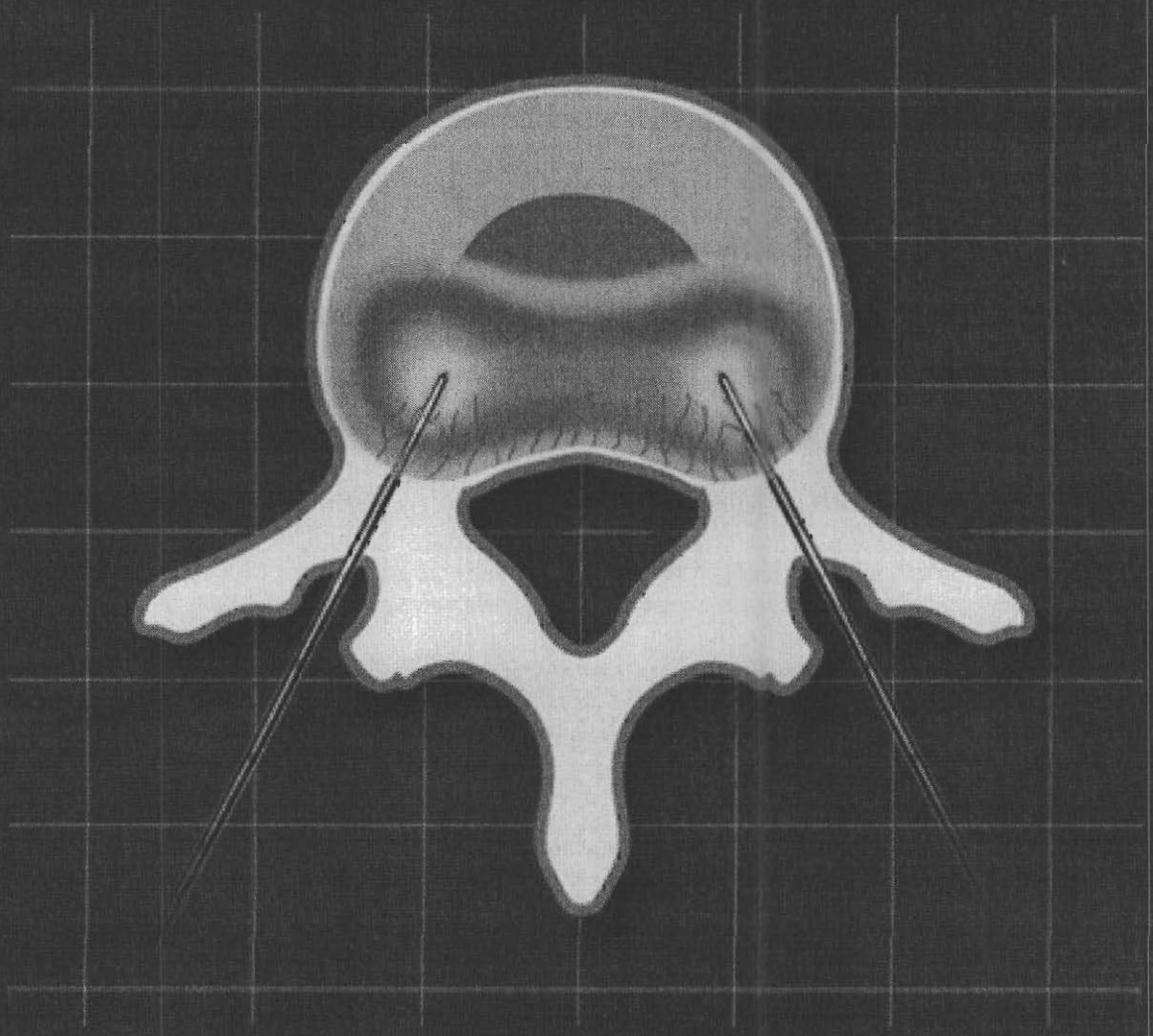

DISC BIACUPLASTY – Clinical Review

A new and effective option to treat intractable discogenic back pain

Table of contents:

Executive Summary 3
Background on Discogenic Back Pain 4
  Treatment Options for Chronic Discogenic Pain 5
The Disc Biacuplasty Procedure 6
  Description of Disc Biacuplasty 6
  Disc Biacuplasty is Not IDET 7
  Disc Biacuplasty is Not PIRFT 10
  Disc Biacuplasty is Not Annuloplasty 11
Evidence in Support of Disc Biacuplasty 12
  Summary of Evidence 12
  Studies of Disc Biacuplasty 13
Indications for Use 16
  Patient Selection Criteria 16
  Clinical Vignettes 17
Economic Context 19
  Cost Comparisons 19
Regulatory Approval 21
Clinical Training 22
  Physician Education: Towards Repeatable Outcomes 22
Appendix A1- 510(k) 23
References 24

Executive Summary

Low back pain is a very common affliction. Fortunately, the majority of patients who experience low back pain obtain adequate relief with conservative management. Even severe cases of back pain respond reasonably well to intensive non-operative management. However, studies show that after six (6) months of chronic pain, the likelihood of conservative therapy giving positive results drops dramatically. Patients with ongoing pain face the options of continued narcotic use or spinal fusion. Disc biacuplasty represent an alternative treatment option for these patients.

Intervertebral disc biacuplasty is a minimally invasive procedure for treating chronic axial discogenic back pain. It is proposed for patients who have not received relief after undergoing an optimal course of conservative therapy. **This procedure is applicable to only a very specific sub-set of patients suffering from chronic, axial, low back pain of discogenic origin who, based on diagnostic evidence, are likely to achieve clinically relevant improvements in pain severity, disability, drug usage, return to work, and overall quality of life.** The sub-set of patients who may benefit from the intervertebral disc biacuplasty is described in detail in section "Indications for Use".

Disc Biacuplasty is performed by inserting two internally-cooled radiofrequency focal electrodes into the posterior lateral aspects of the painful intervertebral disc. Radiofrequency energy is directed between the two focal electrodes, heating the tissue of the posterior annulus and ablating the nociceptive nerve fibers while at the same time cooling the tips to ensure proper temperature profiles. This treatment addresses the proposed pathophsysiology of discogenic pain, while maintaining the native spinal structure and biomechanics.

The efficacy of the disc biacuplasty is supported by two prospective clinical outcome studies and a case series. A study, conducted at the Cleveland Clinic, demonstrated a 53% reduction in pain intensity and a 28% reduction in functional disability among 15 patients at 6-month follow-up. These results were corroborated in a second study, performed by Dr. William Whyte in private practice at Louisiana Pain Specialists. **Based on these clinical studies and data from other centers, 60% of patients treated with disc biacuplasty will experience clinically significant improvements in pain and functional status**. These outcomes compare favorably to improvements reported for fusion surgery. Furthermore, disc biacuplasty has demonstrated a low risk of complications compared to fusion surgery.

It is important to note that disc biacuplasty is not IDET which was developed to treat annular disruptions of contained herniated discs. IDET uses a resistive heating element that is difficult to control and provides superficial heat adjacent to the wire. Disc biacuplasty uses RF energy to produce a controlled zone of ablation that includes the nociceptive nerve ingrowths. Biacuplasty represents a fundamentally different modality of treatment than IDET

From an economic perspective, disc biacuplasty compares very favorably to either fusion surgery or continual narcotic management. Disc biacuplasty is a minimally invasive procedure with a high success rate and low complications rate at a reasonable cost.

Background on Discogenic Back Pain

Low back pain is one of the most prevalent medical conditions afflicting the population today. Fortunately, the majority of patients who experience an episode of low back pain will obtain adequate relief with time and conservative management. Even refractory cases of severe back pain respond reasonably well to intensive non-operative management [11]. However, approximately 5% of patients will continue to experience severe pain and functional impairment chronically [6]. Not surprising to those who work in the field, almost 90% of healthcare costs for low back pain are consumed by this group of patients [16].

A number of biomechanical and neurologic components have been implicated in the etiology of chronic low back pain [3]. Internal disc disruption is associated directly with chronic pain in an estimated 40% of patients reporting persistent symptoms of unknown origin [20]. The pathophysiology of internal disc disruption (IDD) and discogenic pain remains largely unknown. However, pain correlates with delamination, fissuring, micro fractures of the collagen fibrilles, and sensitization of the nociceptors inside the annulus fibrosus [5]. Histological studies suggest that in response to disc degeneration and lamellar disruption, neo-vascularization, and neuronal penetration with unmyelinated nerve fibers occurs [7,10]. It has been observed that at least a portion of this neo-innervation provides a sensory function, potentially acting as a pain generator [7,10]. The ablation of these pain generating nerve fibers is proposed as a viable treatment for the management of discogenic pain [14,21].

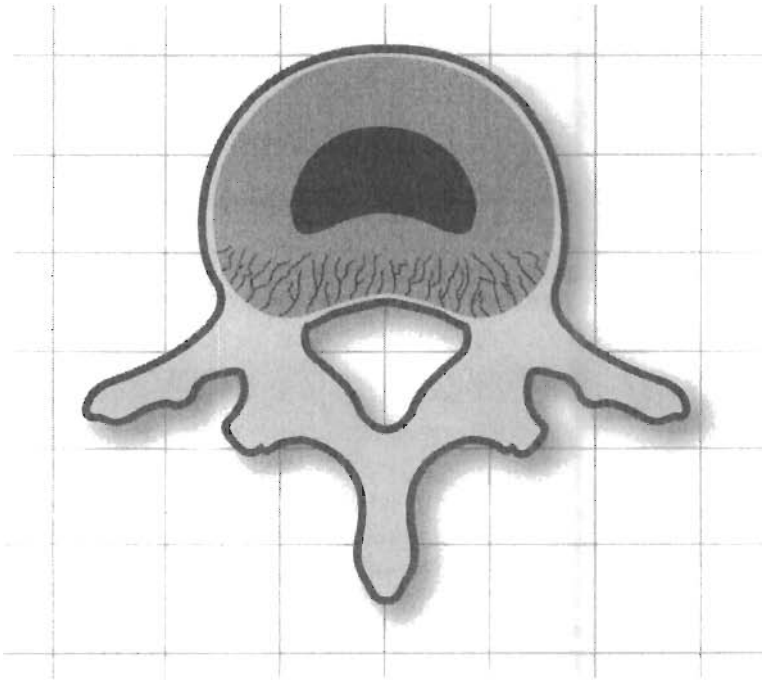

Figure 1: Innervation of Degenerated Disc

Treatment Options for Chronic Discogenic Pain

Conservative Therapies are generally the first option for patients suffering from low back pain. However if the pain becomes chronic and intractable, lasting longer than six months, the chances of recovery with non-operative management alone are not good [4,6]. Under the current continuum of care, patients suffering from chronic back pain may either:

a. Continue living with their chronic pain, suffering with disability, drug usage, inability to work, and poor overall quality of life. It should be noted that these patients place a large financial burden on the health care system, as they continually use the system seeking relief.

b. Opt for spinal fusion surgery with a moderate prognosis for recovery, but face moderately high risk of complications, and incur much higher costs

Disc biacuplasty offers a minimally invasive treatment option for a subset of patients suffering from chronic, (greater that 6 months), **axial** back pain. Disc biacuplasty does not pertain to radicular pain originating from herniated discs.

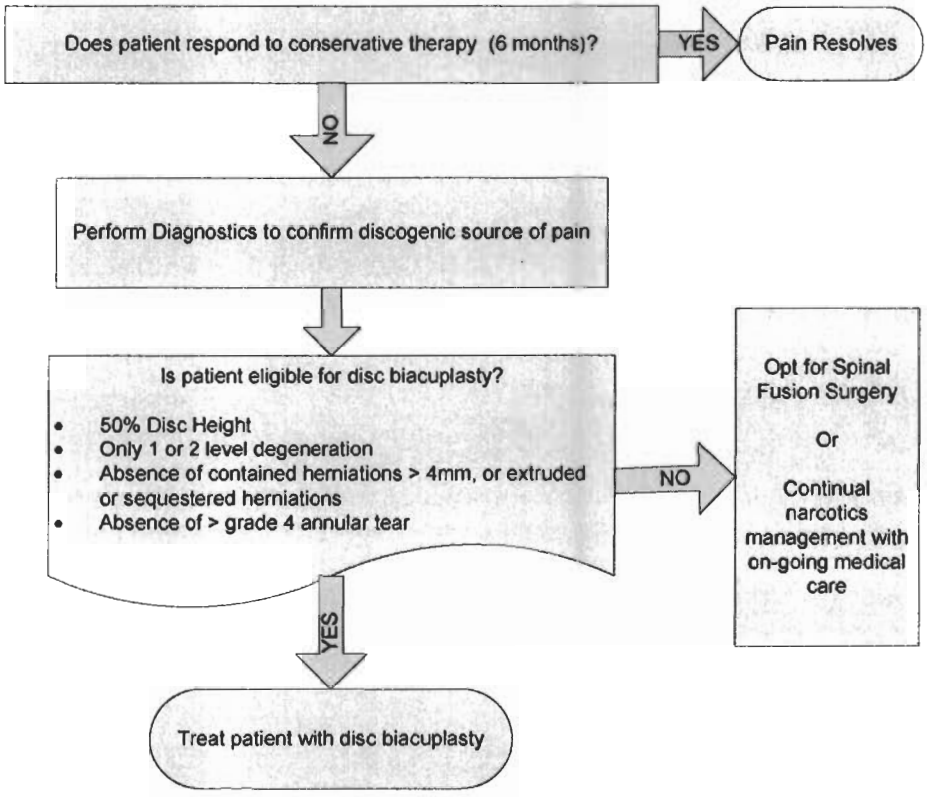

Figure 2: Continuum of care with disc biacuplasty

The Disc Biacuplasty Procedure

Description of Disc Biacuplasty

Disc biacuplasty is performed by positioning two radiofrequency electrodes within the posterolateral aspects of the intervertebral annulus fibrosus. Radiofrequency energy is directed between the probes, heating the tissue of the posterior annulus and ablating the nociceptive nerve fibers. The focal electrodes are cooled during the delivery of the RF energy to ensure that the proper heating profile is achieved.

The procedure is performed by board certified pain management physicians familiar with fluoroscopically guided spinal interventions.

Disc biacuplasty is a relative simple and reproducible procedure. Electrode placement is familiar to physician by virtue of the procedural similarity to discography. Once the electrodes are placed in the posterior lateral corners of the disc (mid-way between the adjacent vertebral endplates), the TransDiscal system ensures appropriate heating in each patient, regardless of individual differences in disc shape. After positioning the electrodes in the posterior corners of the disc, the resulting heating profile is such that the entire volume of the posterior annulus reaches neuroablative temperatures [14,17].

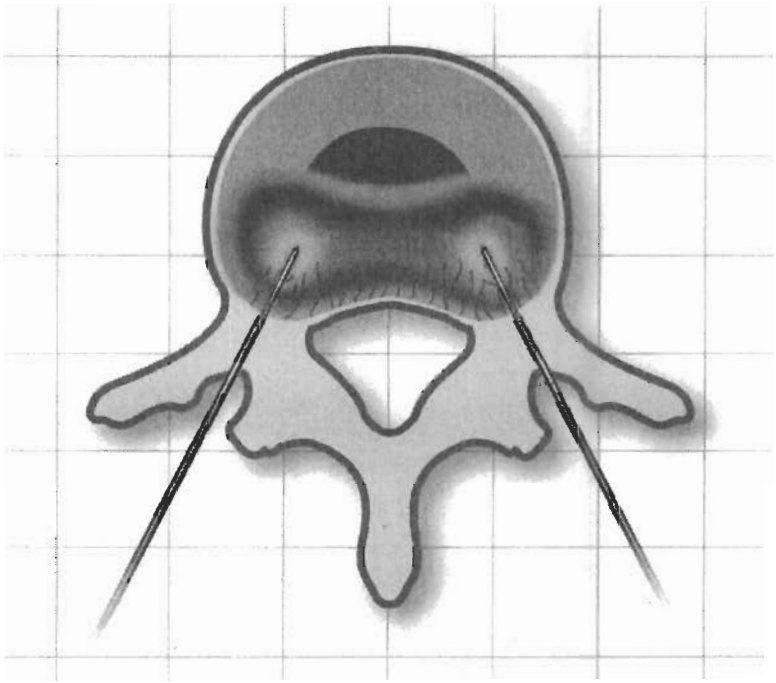

Figure 3: Disc Biacuplasty
Placement of electrodes and effective region of neuroablation

Disc Biacuplasty is Not IDET

Focal RF Technology

Disc Biacuplasty is a focal radiofrequency (RF) system. Focal RF systems consist of a needle or catheter with an active focal electrode at the tip. Focal RF can be of the Standard-RF or Cooled-RF. In Cooled-RF, the electrodes are cooled while the RF energy is delivered. This cooling allows for the creation of a larger, more diffuse lesion. The focal electrode is used to inject radio frequency current through a part of the body so as to:

- Ablate a cancer
- Ablate an extra conductive cardiac tissue
- Ablate a pain generating nerve
- Ablate a part of the Prostate

There is over 40 years of clinical experience with focal RF systems. A broad and vast amount of literature supports the approach of thermal lesioning of nerves based on the use of ionic heating through the application of RF electricity. Focal radiofrequency systems have been used in the following fields:

- Standard-RF deep brain lesioning to treat inoperable cancer
- Cooled-RF liver lesioning to treat liver cancer
- Standard-RF cardiac ablation to treat accessory pathways
- Cooled-RF cardiac ablation to treat atrial flutter
- Cooled-RF ablation of Benign Prostatic Hyperplasia (BPH)
- Standard-RF for varicose vein shrinking treatment
- Standard-RF lesioning to treat facet joint pain
- Cooled-RF lesioning to treat discogenic pain (Disc Biacuplasty)

Cooled-RF applied focally has been introduced whenever a larger lesion was required. In brain cancer treatment, small, precise lesions are required and consequently Standard-RF is used. However to treat liver cancer, large broad lesions are required and therefore Cooled-RF is used.

In cardiac ablation, precise lesions are required when treating AVNRT or WPW accessory pathways in the right atrium of the heart. However the treatment of atrial flutter requires a lesion to cover a broad area, therefore Cooled-RF is used.

In the treatment of Benign Prostatic Hyperplasia, the large prostate must be treated. Therefore Cooled-RF is used for this application.

In the treatment of pain management, Standard-RF is used when denervating nerves in facet joint or the peripheral areas as precise lesions are required. Now disc biacuplasty makes use of Cooled-RF for denervating nerves in the posterior of an intervertebral disc as larger lesions are required to effectively treat the entire area. Disc biacuplasty uses Cooled-RF technology to vastly increase the size of lesion that is possible with Standard-RF. With this, it is possible to heat large volumes of tissue with RF energy while maintaining control of the lesion properties; shape, size and temperature.

In summary, disc biacuplasty uses a focal Cooled-RF system and is built upon decades of positive results in many areas of medicine that use both Standard-RF and Cooled-RF. These clinical benefits have been documented in thousands of published studies. The same action of effect that brings results in the approved facet joint denervation is used when treating the disc with disc biacuplasty. The major difference is in the use of a Cooled-RF system.

IDET Technology

Percutaneous intradiscal electrothermal therapy (IDET) was introduced in 1996 as a minimally invasive alternative to fusion surgery to treat patients with annular disruptions of contained herniated discs.

IDET consists of using a resistive heating element to treat a disrupted disc. The heating element is similar in function to what is used in a household toaster. The IDET system does not apply radiofrequency energy into the tissues. IDET does not build on the vast clinical experience utilizing radiofrequency energy to ablate tissue.

IDET introduces a wholly new concept of using a resistive heating coil. There are no other applications that the author knows of that use a resistive heating coil for a therapeutic effect.

In addition, it has been shown that IDET does not reach therapeutic temperatures throughout the posterior annulus of the intervertebral disc [9,15]. In contrast, disc biacuplasty reaches therapeutic temperatures throughout the posterior annulus of the intervertebral disc [17].

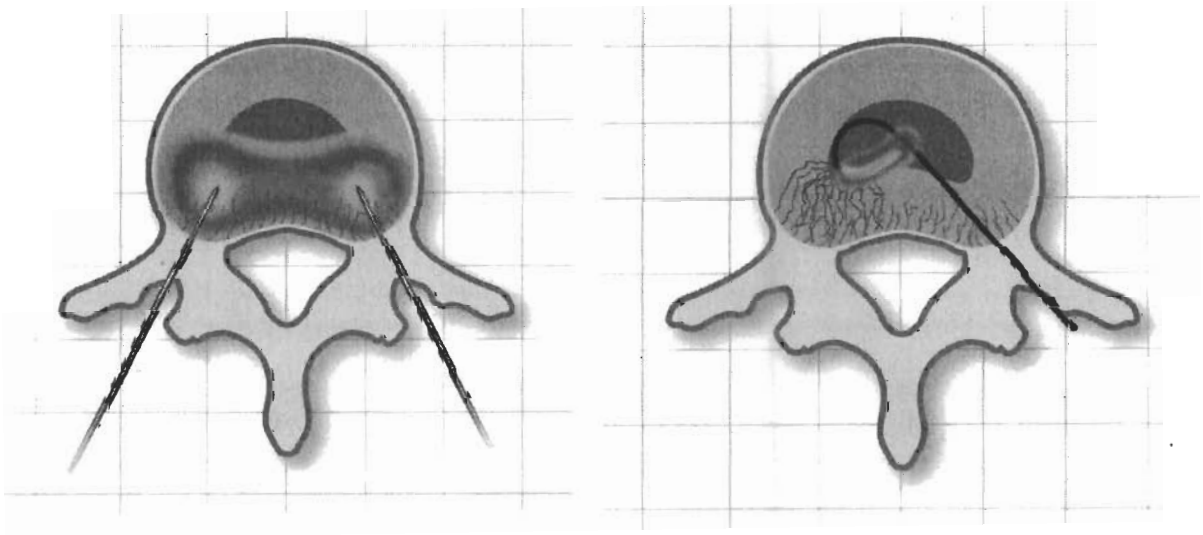

Disc Biacuplasty **IDET**

Figure 4: Disc treatment profile and mechanism
Disc biacuplasty versus IDET

Disc biacuplasty is a fundamentally different modality of treatment than IDET. Disc biacuplasty uses well known focal RF applications in a Cooled-RF mode to ablate nerve ingrowths. It is not a refinement or a derivative of IDET.

Disc Biacuplasty is Not PIRFT

PIRFT - Percutaneous Intradiscal Radio Frequency Thermo-coagulation

Barendse et al. described a study wherein they found that Percutaneous Intradiscal Radiofrequency Thermo-coagulation was not effective [2]. Their study consisted of inserting a Standard-RF facet denervation electrode into the center (nucleus pulposus) of a disc.

Facet denervation is a very common and successful procedure wherein Standard-RF energy is used to ablate the facet nerve in order to treat facet joint pain. In facet denervation, the RF electrode is placed on top of the nerve to be ablated. It creates a spherical lesion that is a few millimeters in diameter and destroys the targeted nerve. To effectively ablate a pain generating nerve with Radio Frequency, the nerve must be treated at a temperature above 45 degrees Celsius for approximately 90 seconds

The hypothesis of the Barendse study was that the heat induced by a Standard-RF lesion in the nucleus pulposus of the disc would propagate by convection to the outer annulus. The outer annulus would in turn be heated to above 45 degrees Celsius and thereby ablate the nocioceptive fibers. Subsequent studies have shown that there was no convection of heat whatsoever [13]. As such the study never delivered any therapeutic treatment to any part of the annulus of the disc. Thus the lack of efficacy that was reported by Barandese et al is not surprising.

In contrast Disc biacuplasty positions the Cooled-RF electrodes in the posterior corners of the disc; the resulting heating profile is such that the entire volume of the posterior annulus reaches neuroablative temperatures [14,17].

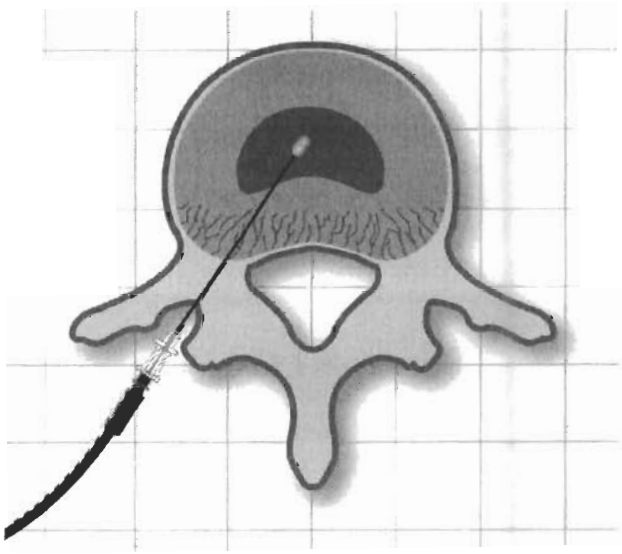

Figure 5: Profile of Barandese Study
Standard-RF Facet Denervation Electrode in nucleous pulposous

Disc Biacuplasty is Not Annuloplasty

There exists some confusion between the "disc biacuplasty" procedure and the "annuloplasty" procedure. Disc biacuplasty is not annuloplasty.

Annuloplasty uses heating to coagulate and decompress disc material so as to treat annular disruptions of contained herniated discs.

Disc biacuplasty uses known Radio Frequency lesion creation techniques to ablate nerves in the disc. Disc biacuplasty is performed using the TransDiscal system that was cleared by the FDA for the creation of Radio Frequency lesions in nervous tissue including that which is situated in intervertebral disc material.

Evidence in Support of Disc Biacuplasty

Summary of Evidence

The currently available evidence supporting disc biacuplasty includes:

- Case reports
- Abstracts
- Two prospective clinical outcome studies being published within the calendar year of 2007
- An RCT (randomized controlled trial) under way at the Cleveland Clinic conducted by Dr. Leonardo Kapural

The available data on the disc biacuplasty procedure makes a strong medical argument in its favor. **60% of patients who meet the strict inclusion criteria for disc biacuplasty will experience clinically significant improvements in pain and functional status.** This includes reduction of opiod use. This data is even more compelling when compared to the current standards of care; fusion surgery and chronic narcotic management.

Importantly, disc biacuplasty has not been associated with any post procedure complications in over 200 cases performed. This is in stark contrast to fusion surgery, in which reported perioperative complication rates range from 2% to 54% (median 14%) in 31 study groups [1]. These surgical complications included instrument failure, infection and/or pain at the donor site (usually the iliac crest), neural injuries, pulmonary embolus and infection at the surgical site [19]. All patients who have had fusion are left with diminished range of motion.

Due to the minimally invasive nature of disc biacuplasty, post-operative recovery time is short. Patients typically resume normal levels of activity within one week. Restrictions on certain lifting and bending activities are removed after 4-6 weeks of post operative rehabilitation. This is also in contrast to invasive surgical techniques, which are associated with longer, more intensive rehabilitation programs.

Studies of Disc Biacuplasty

The disc biacuplasty procedure has been developed and validated in a stepwise, evidence-based manner. Studies to date include:

Animal/Cadaver Studies

Acute Histological Effects and Thermal Distribution Profile of Disc Biacuplasty Using a Novel Water-Cooled Bipolar Electrode System in an *in vivo* Porcine Model Petersohn J, Conquergood L, and Leung, M *Pain Medicine 2007*

The authors note prior evidence of innervation of the lumbar disc as a rationale for interventions on the posterior annulus of the disc. This study involved performing disc biacuplasty on 7 porcine lumbar discs and two control discs in two anesthetized pigs. Intra-procedure temperatures were monitored at various anatomical locations. The animals were then euthanized and the discs prepared for histological examination.

Major findings and conclusions:

- Disc biacuplasty in a porcine model achieved suitable temperatures to induce transition of collagen and thermolysis while showing no evidence of damage to neural tissue in safety zones surrounding the disc.

Histological and Temperature Studies of a Novel TransDiscal Heating System in Human Cadaver Discs Kapural L, Mekhail N, Kapural, Hicks D , M.D. Pain Management, Cleveland Clinic, Cleveland, Ohio Presented at the American Society of Anesthesiologists *Anesthesiology 206; 105: A705*

The authors note that two earlier intradiscal lesioning techniques, intradiscal thermal (IDET) and radiofrequency annuloplasty (PIRFT) may have had limited therapeutic effect because of their minimal annulus denervation activity and inability to induce a collagen repair. This study examined the temperature and histological effects of biacuplasty on 8 lumbar discs from two human cadavers compared with control discs from each cadaver.

Major findings and conclusions:

- Temperature – The temperature between the two probes in the inner annulus was greater than 50 °C in 8 out of 8 cases. Temperatures in the epidural space were below 43 °C in 8 out of the 8 discs treated. Temperatures around the nerve root area were below 43 °C in 8 out of the 8 discs treated. Thus temperatures for ablating nociceptors are reached. The disc biacuplasty heating pattern had a desired temperature distribution in the annular part of the discs, without overheating adjacent structures.
- Histology - There was no end-plate or subchondral bone changes which could be attributed to localized heating.

Clinical Studies

Novel Intradiscal Biacuplasty (IDB) for the Treatment of Lumbar Discogenic Pain Kapural L and Mekkhail N *Pain Practice Vol 7 Issue 2 2007 130-134*

This is a pilot study involving a single 31 year old patient who had experienced persistent and debilitating discogenic back pain of 2.5 years duration following an accident.

Major Findings and Conclusions:

- The procedure was well tolerated. There were no intraoperative or postoperative complications.
- Patient experienced the following improvements:

	Baseline	*6 months after procedure*
VAS	5	1
Oswestry	14 points	6 points
SF 36 physical function	67	82
SF 36 role physical	75	88
SF 36 pain	68	80
SF 36 general health	80	90
SF 36 vitality	70	75
SF 36 role emotional	100	100
SF 36 mental health	60	80

A Novel Radiofrequency System (Intervertebral Disc Biacuplasty) for the Treatment of Lumbar Discogenic Pain: Results of a 6-Months Pilot Study Kapural L, Ng, A, and Mekhail N *Presented at AAPM. Journal Publication Pending*

This Cleveland Clinic study involved 15 patients with discogenic back pain of prolonged duration (range 1-20 years, average 5.8 years of pain). Inclusion criteria required back pain greater than leg pain and pain reproduction on provocative discography (not present on control discs.) and single-level or two-level degenerative disc disease without evidence of additional degenerative changes in other disc spaces on MRI. Exclusion criteria included evidence of compressive radiculopathy, disc herniation on MRI, and spinal stenosis.

Major findings and conclusions:

- Patients having disc biacuplasty using the TransDiscal system demonstrated substantial and statistically significant improvements in both pain scores and functional capacity. There were no serious adverse events or complications.
- Improvement was apparent at one month following procedure and persisted at 6 month evaluation. 12 month outcomes are pending.
- There was an observed decrease in opiod use but it was not statistically significant

Mean Scores	Baseline	1 month	p (from baseline)	6 months	p (from baseline)
Oswestry	23.3 +/-7.0	16.5 +/-6.8	0.001	17.1 +/-8.1	0.002
VAS	7.2 +/-1.9	3.3 +/ 2.1	0.000	3.4 +/-1.9	0.00
SF 36 PF	50.8 +/- 17.5	59.4 +/-13.0	0.053	69.9 +/- 16.2	0.002
SF 36 PB	37.5 +/-15.0	49.7 +/-19.3	0.02 0	53.8 +/-22.7	0.003

Clinically Significant Reduction in Discogenic Pain Following Intervertebral Disc Biacuplasty Treatment: Results of a 6-Month Follow-up Study Whyte, William

This community based study by Louisiana Pain Physicians involved 15 patients with low back pain unresponsive to non-operative care for at least 6 months, back pain greater than leg pain and concordant pain reproduced on discography.

Major Findings and Conclusions

- At 6 months there was an approximate 60% reduction in pain intensity (VAS) and a 30% reduction in disability (Oswestry).
-

Mean Scores	Baseline	1 month	p (from baseline)	6 months	p (from baseline)
Oswestry	36.4 +/-17.1	21.8 +/-10.2	0.04	26.7 +/-22.4	0.25
VAS	7.7 +/-0.7	2.8 +/ 2.3	0.006	3.2 +/-3.0	0.012

Disc biacuplasty for treatment of axial discogenic low back pain- initial case series. Cooper, A. R.

This study performed in Northern Ireland was conducted on 8 patients who had back pain of greater than 6 months duration and had failed to achieve sustained relief with facet joint injections, sacroiliac joint injections, and RF rhizotomies.

Major Findings and Conclusions

- Pain assessed by was noted to respond from 0-90% at 6 months. One patient had no response. Two patients achieved a response of 20% and 30%.
- 4 of 8 patients achieved greater than 50% reduction in pain.
- There were no adverse events or complications

Pending Studies

A randomized placebo controlled trial of disc biacuplasty is currently being conducted at the Cleveland Clinic.

Indications for Use

Disc Biacuplasty is indicated for a specific sub-set of patients suffering from chronic **axial** low back pain of discogenic origin. Based on clinical evidence, these patients are likely to receive clinically relevant improvements in pain severity, back function, reduction in drug usage, return to work options, and quality of life.

In order to be considered eligible for disc biacuplasty, patients must satisfy strict selection criteria. These criteria, (including assessment of possible pain generators and disc degeneration such as tears, hernias, and disc height), must all be reviewed by the treating physician to ensure likelihood of a successful treatment. **Practicing physicians have estimated that approximately 10% of patients suffering from chronic discogenic pain, (who have failed conservative care), meet the selection criteria for disc biacuplasty.** This treatment option maintains the native biomechanics of the spine, and in no way limits future treatment options.

Patient Selection Criteria

Indications for Use

- Criteria for discogenic pain satisfied, viz.
  - Predominant axial/mechanical back pain.
  - Demonstration of positive concordant pain of intensity >6/10 during provocative lumbar discography at 1 or 2 disc levels at low pressures (< 50psi) with negative control disc at one and preferably two adjacent levels and sham pressurization.
  - Physical Examination
- Chronic Pain (>6 months)
- Age greater than 18 years
- At least 50% preserved disc height
- Failure to achieve adequate improvement with comprehensive non-operative treatment including: non-steroidal anti-inflammatory, physical therapy, and fluoroscopically guided epidural steroid injection in and around the area of pathology.
- Other possible causes of low back pain have been ruled out eg. Failure to obtain prolonged improvement (>14 days> from facet injections, sacroiliac joint injections or RF rhizotomies.

Contraindications

- Neurological deficit.
- Intervertebral disc herniations greater than 4mm.
- Extruded/sequestered intervertebral disc herniations.
- Spinal Pathology that may impede recovery such as spina difida occulta, spondylolisthesis at the painful segmental level or scoliosis.
- Moderate to severe foraminal or central canal stenosis.
- Pregnancy
- Existing endplate damage or Schmorl's nodes.
- Greater than grade 4 annular tear (Modified Dallas Grading)
- Systemic infection or localized infection at the anticipated introducer endty site
- History of coagulopathy or unexplained bleeding.

Clinical Vignettes

Below are two samples of patients being successfully treated with disc biacuplasty.

Sample Case 1 - Disc Biacuplasty

A 47 year old male carpenter injured his lower back at work while lifting drywall. Since the injury, the patient relied heavily on friends and family for assistance in activities of daily life living. He experienced high levels of pain, with a VAS score pre-procedure of 8, and failed conservative treatments including physical therapy, epidural injections, and medications.

A discogram and MRI were performed and this lead to the recommendation for a disc biacuplasty procedure. The patient received treatment on July 26, 2007 at disc level L5-S1.

Within one month, the patient's pain score (VAS) dropped from 8 to 4. The patient is currently in his recovery phase and will start physical therapy on August 31, 2007 to increase range of motion. Since the procedure, there has been significant progress in pain reduction and a significant increase in functionality. The patient is now able to perform acts of daily living without assistance, such as: bathing, grooming, getting dressed, and getting in and out of the car, which he was not able to do prior to the treatment. The patient is excited to start physical therapy and return to all his daily life activities.

Sample Case 2 - Disc Biacuplasty

A 21 year old male with discogenic pain was limited in performing activities of daily living as well as being unable to engage in sports, dating, or visiting with friends. Importantly, he had to stop working as a Press Operator due to his on-going pain. The patient informed the medical staff that he considers himself to be a young and energetic person. He was very concerned about having to consider early retirement at the age of 21.

The patient had been in the medical system for months seeking relief for his chronic back pain. Previous treatments included physical therapy, epidural injections, and medications. The patient had also undergone a previous nucleoplasty procedure to address his pain symptoms. These all failed to provide relief.

On June 28, 2007 the patient underwent a disc biacuplasty. Two months later, the patient reported a 60-70% improvement post procedure and a very significant increase in the quality of his life. He will be starting physical therapy shortly and is slowly involving himself in day to day activities of a 21 year old male.

The following are two examples of patients who are NOT candidates for disc biacuplasty.

Sample Case 1 – NOT indicated for Disc Biacuplasty

A 67 year old male with diffused spinal degeneration was unable to perform normal daily activities without debilitating pain. The patient suffered from Degenerative Disc Disease at L3, L4, and L5-S1. The patient also showed signs of spinal instability.

Though this patient had heard of disc biacuplasty and was interested in trying a minimally invasive procedure to treat his pain, his condition did not meet the Indications for Use criteria. Of note is that he showed signs of spinal instability. He was subsequently referred to a spinal surgeon for further potential spinal fusion.

Sample Case 2 – NOT indicated for Disc Biacuplasty

A 37 year old female presented with a complaint of low back pain and pain radiating down her right leg. Examination and MRI showed an extruded herniated disc at level L4. The patient had been suffering for over a year with this pain, and had undergone various conservative treatments in an attempt to alleviate the pain.

This patient was interested in avoiding a discectomy procedure and consequently inquired about disc biacuplasty. The patient was informed that disc biacuplasty will not be successful in treating an extruded herniated disc. The patient was subsequently referred to a specialist in minimally invasive discectomy procedures.

Economic Context

Cost Comparisons

There are strong economic arguments for treating patients with the disc biacuplasty procedure. This is particularly so when compared to the high cost of surgery and continual narcotics management.

Presently, the options for patients suffering from chronic axial disc pain that lasts longer than 6 months are:

- Continual narcotic management with on-going medical reviews
- Disc biacuplasty
- Fusion surgery

Continual narcotics management

It has been estimated that continual narcotic management with on-going medical care cost in the order of **$5,500 - $7,500 per year** [22]. This figure only addresses direct medical costs and does not take into account the quality of life issues that directly affect a patient suffering from chronic axial back pain.

Disc biacuplasty

It has been estimated that the average total cost, (professional and facility fees), for a disc biacuplasty procedure is in the range of **$6,000 to $10,000**.

Fusion Surgery

Several studies have reported costs associated with fusion surgery in excess of **$50,000**, with more complex procedures incurring greater costs [12,18].

Complications from fusion surgery have been estimated to be approximately 14%. Of much greater concern are the patients who suffer from Failed Back Surgery Syndrome (FBSS). It has been shown that 5 to 10% of patients who undergo spinal surgery will in fact be worst off after their surgery [8]. This will in turn need to be treated by continual narcotic management with on-going medical reviews.

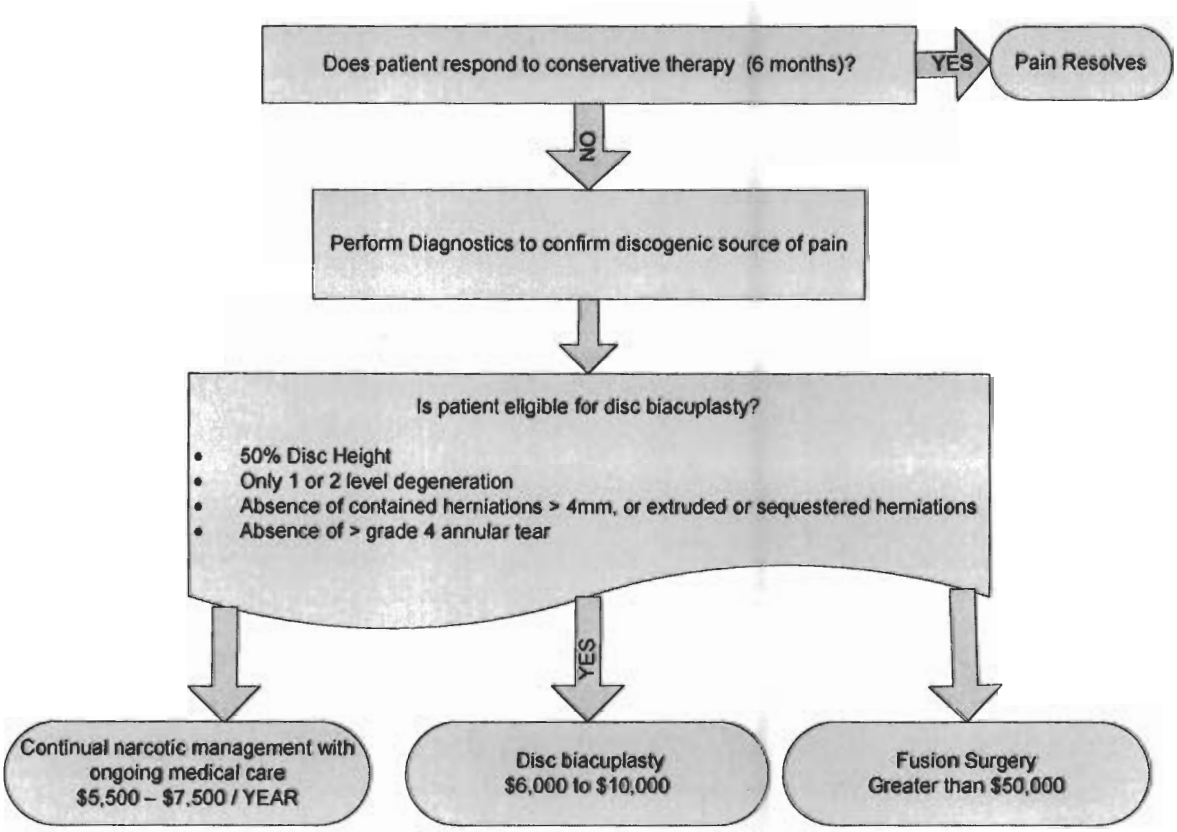

Figure 6: Options and costs for treating chronic discogenic axial low back pain.

Regulatory Approval

The TransDiscal System is cleared by the FDA use in creating Radio Frequency (RF) lesions in nervous tissue including that which is situated in intervertebral disc material (510(k)#K062937) (Appendix A1- 510k).

Clinical Training

Physician Education: Towards Repeatable Outcomes

All physicians who want to perform a disc biacuplasty procedure must undergo **mandatory physician training**.

This training is given by certified physicians from the International Spinal Interventional Society (ISIS), the American Society for Interventional Pain Physicians (ASIPP) and the World Institute of Pain (WIP).

The training involves attendance at a one-day cadaver workshop. At the workshop, a faculty physician provides a three-hour lecture on diagnosis, patient selection criteria, treatment techniques and post procedure care. Following the lecture, each physician trainee performs the procedure and interacts directly with faculty in a hands-on cadaver workshop.

Prior to performing the procedure on their first patient, a clinical support person provides full in-servicing to the medical staff at the hospital or clinic.

After the training, clinical expert is scheduled to attend and support the first cases that the trained physician performs.

References

1. Andersson GB, Mekhail NA, Block JE. Treatment of intractable discogenic low back pain. A systematic review of spinal fusion and intradiscal electrothermal therapy (IDET). Pain Physician 2006;9:237-48.
2. Barendse GA, van Den Berg SG, Kessels AH, et al. Randomized controlled trial of percutaneous intradiscal radiofrequency thermocoagulation for chronic discogenic back pain: lack of effect from a 90-second 70 C lesion. Spine 2001;26:287-92.
3. Bogduk N. The lumbar disc and low back pain. Neurosurg Clin N Am 1991;2:791-806.
4. Brox JI, Sorensen R, Friis A, et al. Randomized clinical trial of lumbar instrumented fusion and cognitive intervention and exercises in patients with chronic low back pain and disc degeneration. Spine 2003;28:1913-21.
5. Burke JG, Watson RW, McCormack D, et al. Intervertebral discs which cause low back pain secrete high levels of proinflammatory mediators. J Bone Joint Surg Br 2002;84:196-201.
6. Carey TS, Garrett JM, Jackman AM. Beyond the good prognosis. Examination of an inception cohort of patients with chronic low back pain. Spine 2000;25:115-20.
7. Coppes MH, Marani E, Thomeer RT, et al. Innervation of "painful" lumbar discs. Spine 1997;22:2342-9; discussion 9-50.
8. Fiume D, Sherkat S, Callovini GM, et al. Treatment of the failed back surgery syndrome due to lumbo-sacral epidural fibrosis. Acta Neurochir Suppl 1995;64:116-8.
9. Freeman BJ, Walters RM, Moore RJ, et al. Does intradiscal electrothermal therapy denervate and repair experimentally induced posterolateral annular tears in an animal model? Spine 2003;28:2602-8.
10. Freemont AJ, Peacock TE, Goupille P, et al. Nerve ingrowth into diseased intervertebral disc in chronic back pain. Lancet 1997;350:178-81.
11. Guzman J, Esmail R, Karjalainen K, et al. Multidisciplinary rehabilitation for chronic low back pain: systematic review. Bmj 2001;322:1511-6.
12. Hacker RJ. Comparison of interbody fusion approaches for disabling low back pain. Spine 1997;22:660-5; discussion 5-6.
13. Houpt JC, Conner ES, McFarland EW. Experimental study of temperature distributions and thermal transport during radiofrequency current therapy of the intervertebral disc. Spine 1996;21:1808-12; discussion 12-3.
14. Kapural L, Mekhail N, Hicks D, et al. Histological and temperature distribution studies of a novel radiofrequency heating system in degenerated and non-degenerated human cadaver lumbar discs. Pain Medicine 2007;In Press.
15. Kleinstueck FS, Diederich CJ, Nau WH, et al. Temperature and thermal dose distributions during intradiscal electrothermal therapy in the cadaveric lumbar spine. Spine 2003;28:1700-8; discussion 9.
16. Nachemson AL. Newest knowledge of low back pain. A critical look. Clin Orthop Relat Res 1992:8-20.
17. Petersohn JD, Conquergood LR, Leung M. Acute histologic effects and thermal distribution profile of disc biacuplasty using a novel water-cooled bipolar electrode system in an in vivo porcine model. Pain Med 2007;In Press.
18. Ray CD. Threaded fusion cages for lumbar interbody fusions. An economic comparison with 360 degrees fusions. Spine 1997;22:681-5.

19. Richardson WJ. Complications in spinal surgery. Current Opin Orthop 1993;4:155-9.
20. Schwarzer AC, Aprill CN, Derby R, et al. The prevalence and clinical features of internal disc disruption in patients with chronic low back pain. Spine 1995;20:1878-83.
21. Smith HP, McWhorter JM, Challa VR. Radiofrequency neurolysis in a clinical model. Neuropathological correlation. J Neurosurg 1981;55:246-53.
22. Stewart WF, Ricci JA, Chee E, et al. Lost productive time and cost due to common pain conditions in the US workforce. Jama 2003;290:2443-54.