

# Procedures on Thoracic Aorta

Sean P Roddy, MD

CPT Advisor, Society for Vascular Surgery  
Chair, SVS Health Policy Committee

*September 19, 2012*

# Request

- Revise the current Body Part value for Thoracic Aorta to differentiate *Descending Thoracic Aorta* from *Ascending Thoracic Aorta/Aortic Arch*.
- There are significant clinical differences in procedural complexity and risk between these two areas.

<i>Section</i>	<b>0</b> Medical and Surgical		
<i>Body System</i>	<b>2</b> Heart and Great Vessels		
<i>Operation</i>	<b>R</b> Replacement: Putting in or on biological or synthetic material that physically takes the place and/or function of all or a portion of a body part		
<i>Body Part</i>	<i>Approach</i>	<i>Device</i>	<i>Qualifier</i>
<b>5</b> Atrial Septum <b>6</b> Atrium, Right <b>7</b> Atrium, Left <b>9</b> Chordae Tendineae <b>D</b> Papillary Muscle <b>J</b> Tricuspid Valve <b>K</b> Ventricle, Right <b>L</b> Ventricle, Left <b>M</b> Ventricular Septum <b>N</b> Pericardium <b>P</b> Pulmonary Trunk <b>Q</b> Pulmonary Artery, Right <b>R</b> Pulmonary Artery, Left <b>S</b> Pulmonary Vein, Right <b>T</b> Pulmonary Vein, Left <b>V</b> Superior Vena Cava <b>W</b> Thoracic Aorta	<b>0</b> Open <b>4</b> Percutaneous Endoscopic	<b>7</b> Autologous Tissue Substitute <b>8</b> Zooplasmic Tissue <b>J</b> Synthetic Substitute <b>K</b> Nonautologous Tissue Substitute	<b>Z</b> No Qualifier

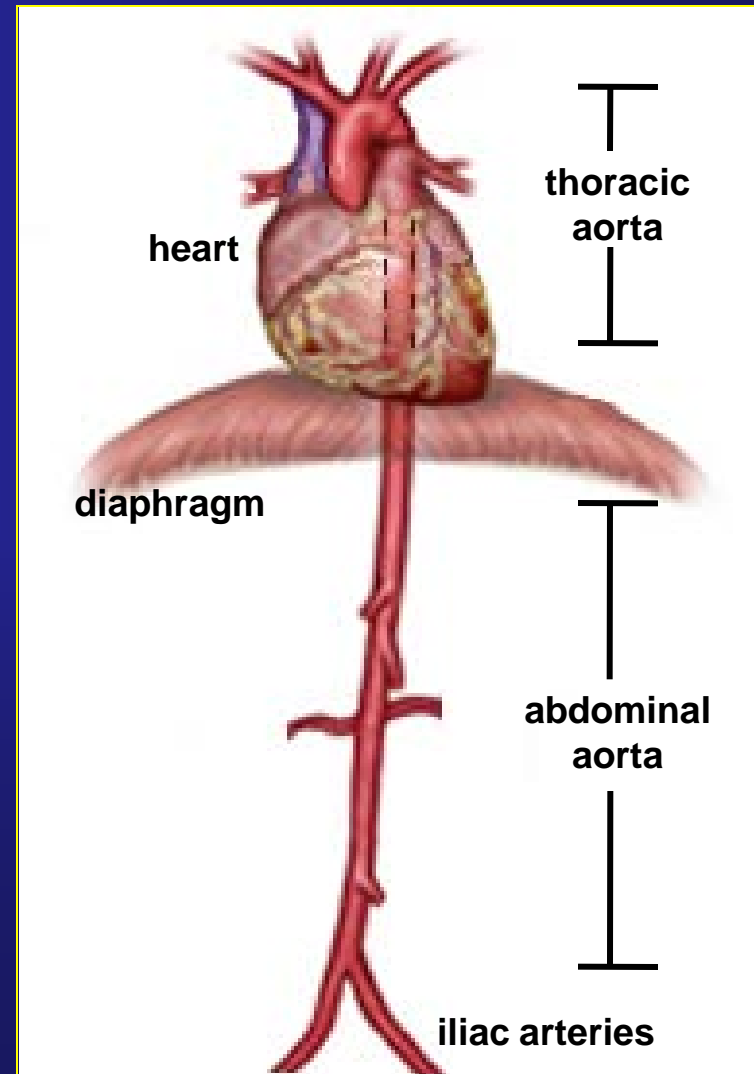
# Anatomy of the Aorta

The aorta originates at the aortic valve, and runs to the mid-abdomen where it bifurcates into the common iliac arteries.

Anatomically, the aorta has two basic portions:

- thoracic aorta
- abdominal aorta

The diaphragm is the dividing line between the two portions.

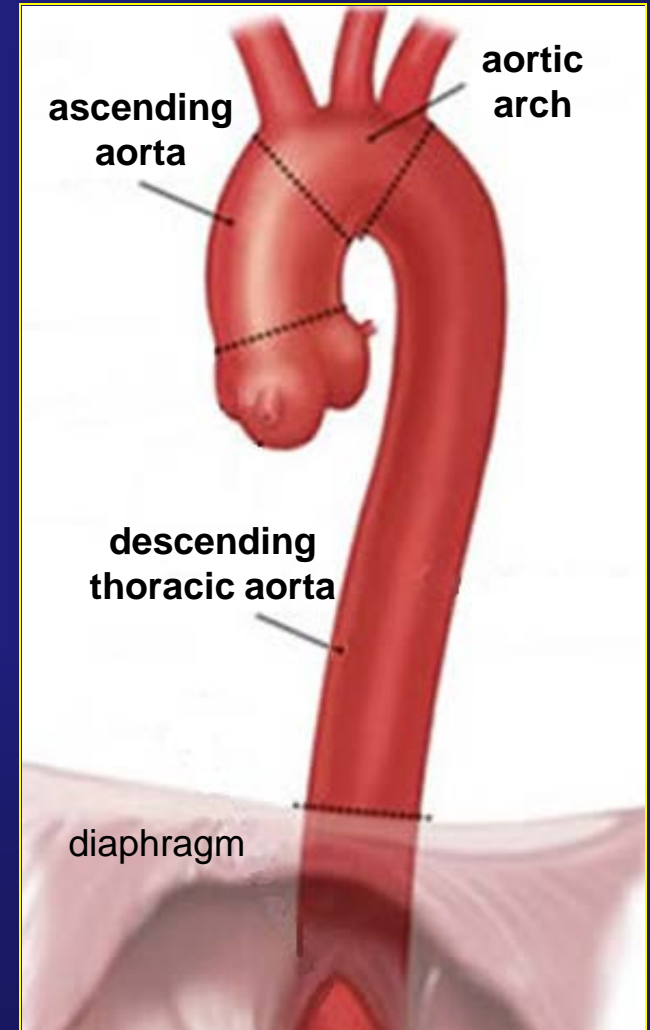


# Anatomy of the Thoracic Aorta

The thoracic aorta has three segments:

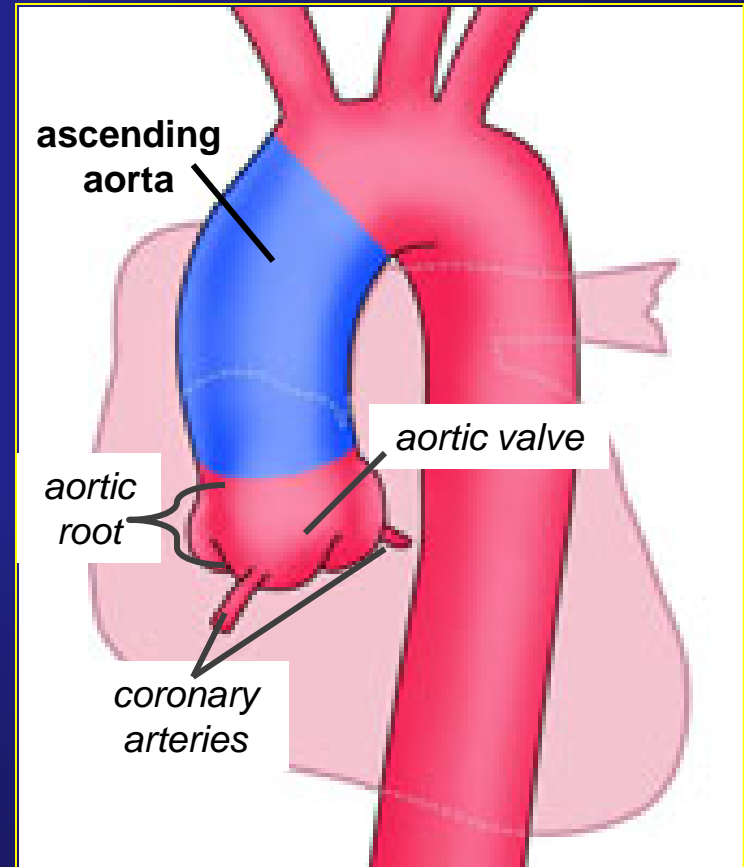
- ascending aorta
- aortic arch
- descending thoracic aorta

Although all part of the thoracic aorta, there are significant anatomic and functional differences between the three segments which greatly impact the choice of surgical treatments, and the risks and outcomes of those treatments.



# Ascending Aorta: Anatomy

- The ascending aorta arises directly from the aortic root.
- The aortic root contains the aortic valve as well as the origins of the left main and right coronary arteries.
- Much of the ascending aorta lies within the pericardial sac.

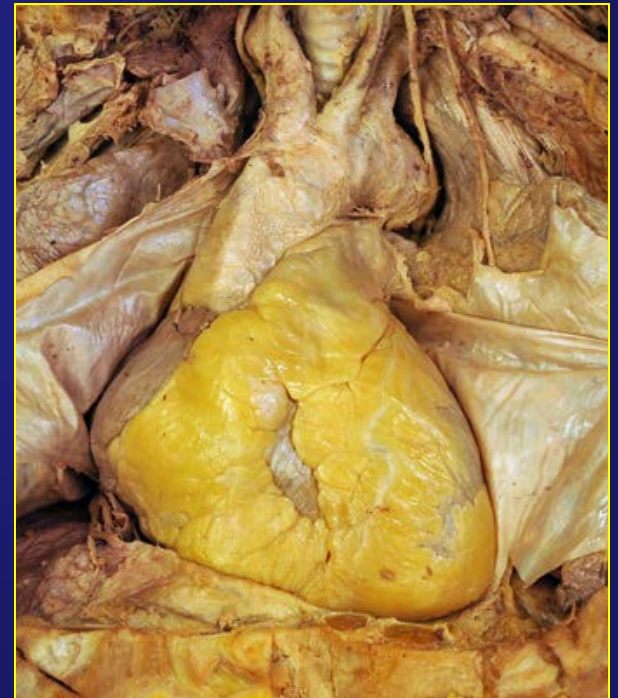

# Ascending Aorta: Procedures

Procedures of the ascending aorta are inherently more complex and carry more risk than those of the descending thoracic aorta. Procedures on the ascending aorta must:

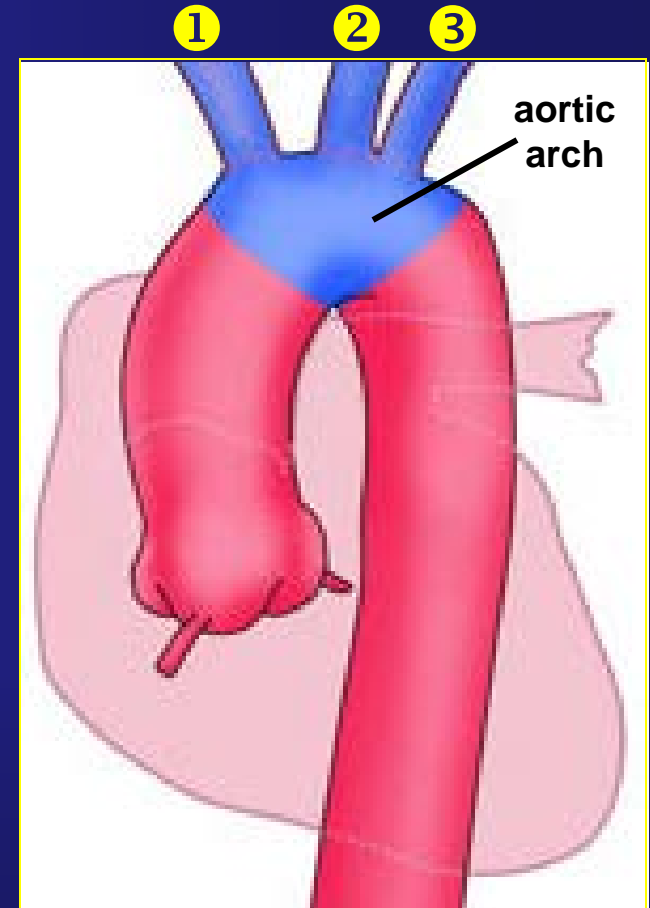
- avoid compromising the aortic valve, or
- involve concomitant valve procedures, and
- preserve blood flow to the heart and brain

For open procedures, the pericardial sac must be entered and then repaired, incurring risk of tamponade.



# Aortic Arch: Anatomy

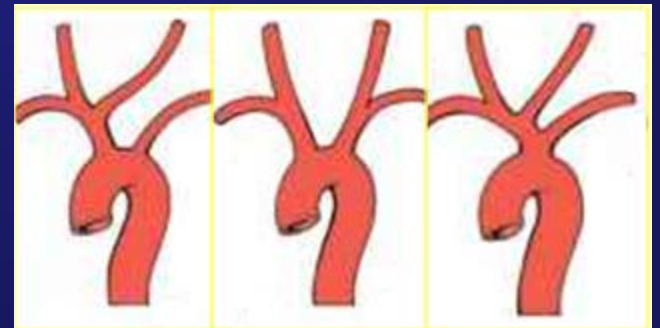
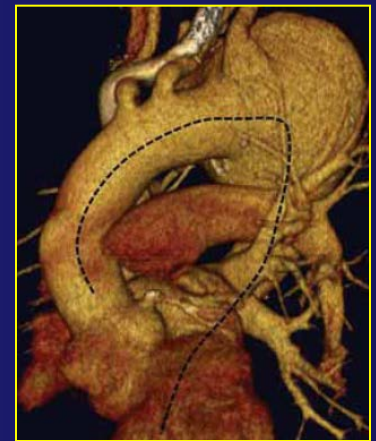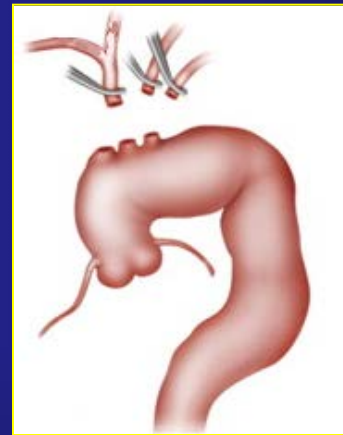
- The aortic arch gives rise to the critical arteries supplying the brain as well as the upper extremities.
  - ① *brachiocephalic (innominate) artery (branching to right common carotid, subclavian and vertebral arteries)*
  - ② *left common carotid artery*
  - ③ *left subclavian artery (with left vertebral branch)*
- The arch may be angulated and full of calcified atherosclerotic plaque, particularly in older patients.
- There are numerous anatomic variations, eg. bovine arch.



# Aortic Arch: Procedures

All arch procedures must preserve blood flow to the vessels supplying the brain, while also managing the risk of plaque, air, or clot embolism.

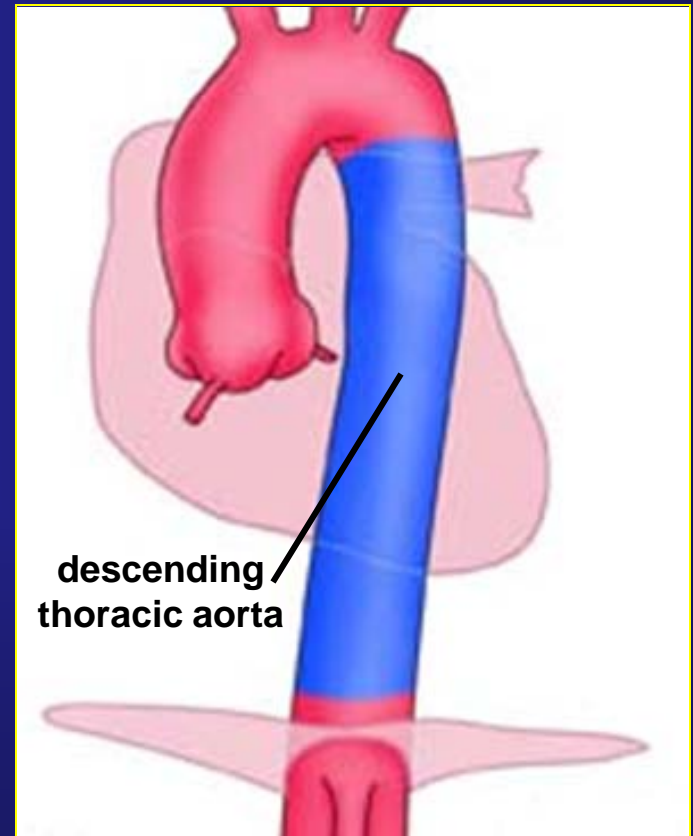
- Open procedures are needed when the arch vessels must be “de-branched”.
- Endovascular procedures require traversing the arch’s curvature and catheterizing the branches.
- Anatomic variations complicate access and use of devices.





# Descending Aorta: Anatomy

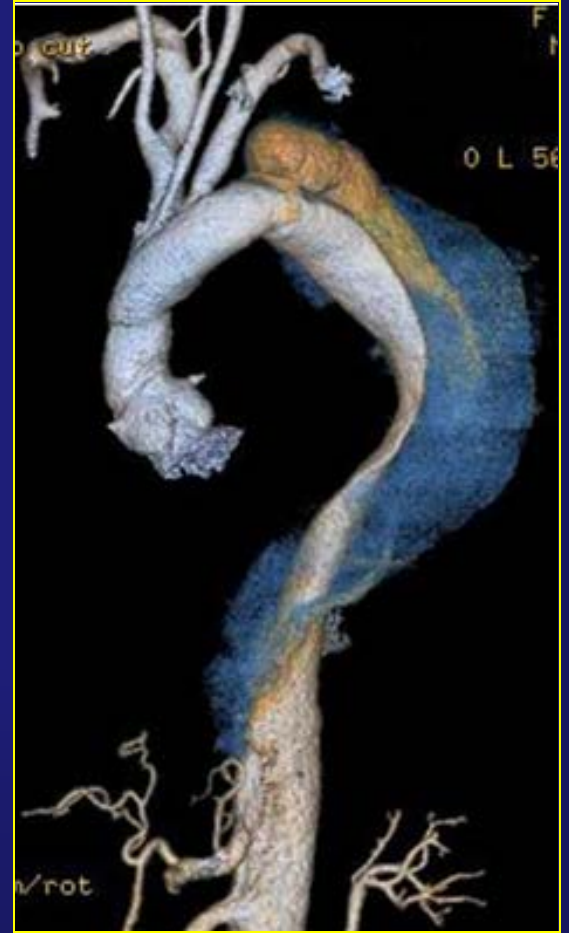- The descending thoracic aorta runs from just beyond the left subclavian artery to the diaphragm.
- It is not directly contiguous with heart structures and does not lie within the pericardium.
- It is comparatively straight.
- Its branches are all thoracic, eg. bronchial, esophageal, intercostal arteries.



# Descending Aorta: Procedures

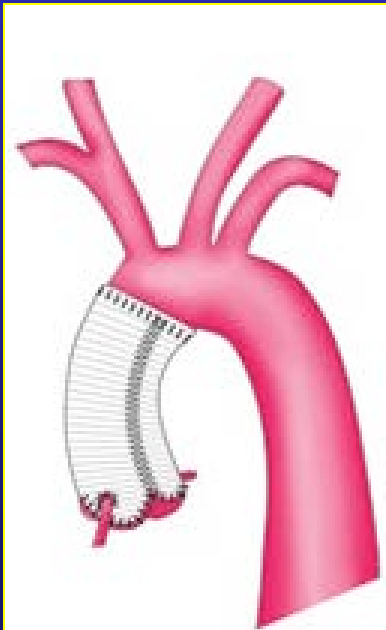
While still major surgery, procedures of the descending thoracic aorta are generally less complex and have less associated risk than those of the ascending aorta and aortic arch.

- Endovascular procedures are facilitated by the descending aorta's more regular configuration.
- Less wire manipulation and branch catheterization is required in the descending aorta.

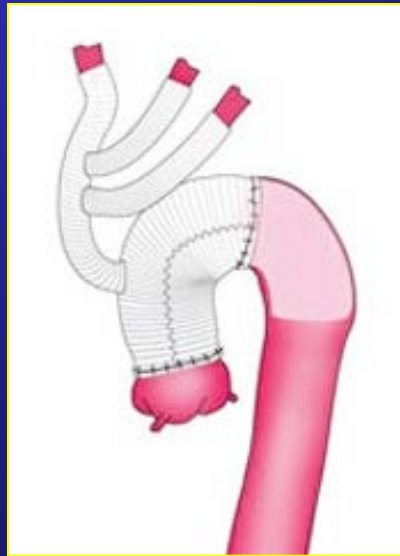


# Comparative Procedures

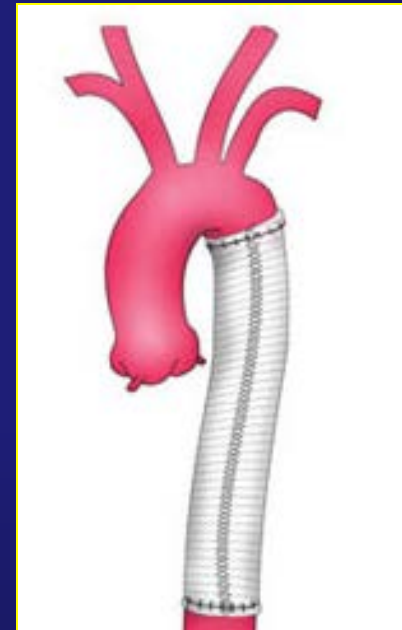
Thoracic aorta procedures commonly include grafts and other repairs for aneurysms and dissections. The segment involved impacts greatly on surgical complexity and risk.



graft of ascending aorta, valve-sparing



graft of ascending aorta and aortic arch with preservation of blood flow to brain

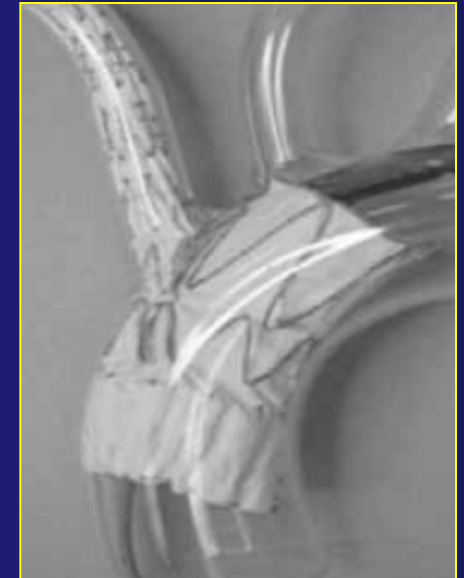

graft of descending thoracic aorta

# Evolution of Thoracic Aorta Procedures

Open and endovascular procedures involving grafts are an area of constant clinical and technological development.

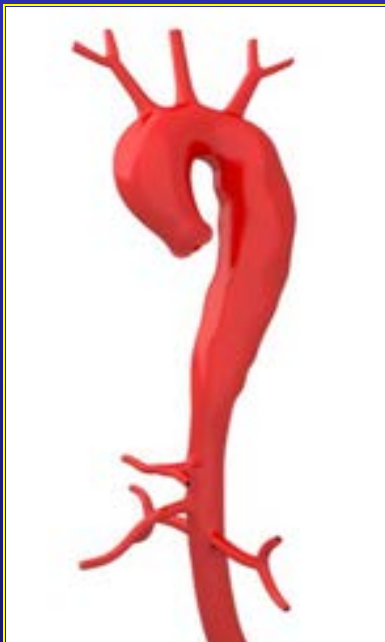- Use of the endovascular approach was first pioneered in the descending thoracic aorta.
- Further development of techniques and devices now enables some endovascular procedures in the arch.
- Although some years off, the ultimate goal is the ability to replace or relined the entire thoracic aorta as necessary.



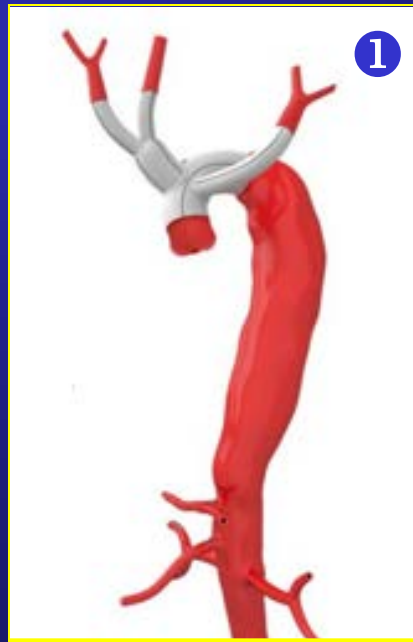
branched endovascular  
graft prototype

# Hybrid Procedures

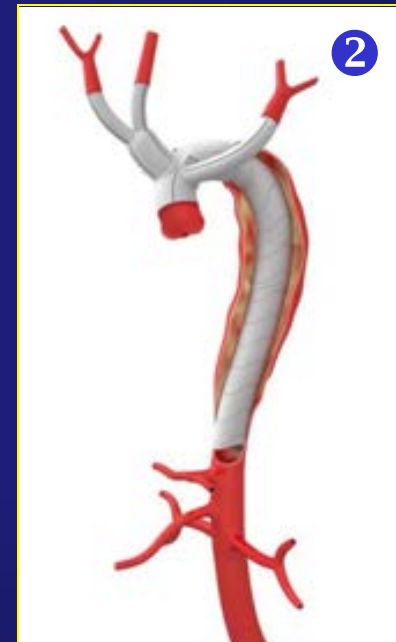Because techniques are still actively evolving, it's common to see hybrid open/endovascular approaches used in different anatomic segments, during the same operative episode.



aneurysm of aortic arch and descending thoracic aorta



graft of aortic arch with limbs to innominate, LCCA and left subclavian arteries, *open approach*

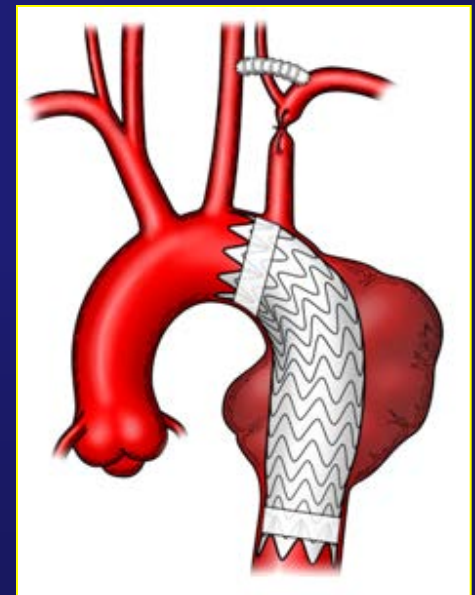
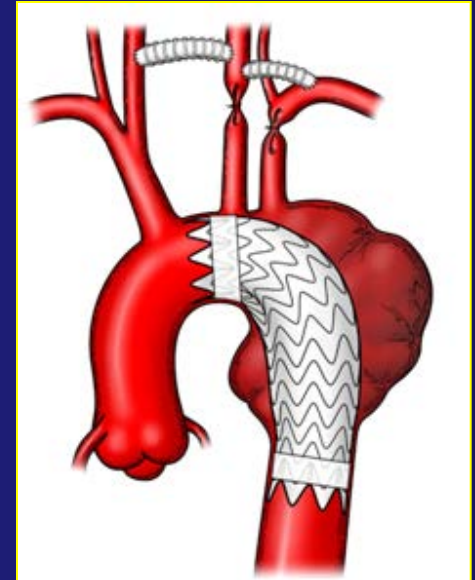


graft of descending thoracic aorta, *endovascular approach*

# Crossing Segments

Procedures sometimes involve more than one segment of the thoracic aorta. For example, it is not uncommon for procedures of the ascending aorta to actively involve the aortic arch.

- When pathology is present in both segments, the procedures in both segments are therapeutic.
- Sometimes a device like a graft extends into another segment without pathology, solely to create a seal in the landing zone.



# Operative Documentation

The segment of the thoracic aorta being treated can be readily identified by the procedure documentation:

- Surgeons generally document the specific segment of the thoracic aorta being treated.
- For open grafts, operative documentation includes the sites of preparatory transection and final anastomosis.
- For endovascular grafts, the distal and proximal deployment sites are documented in the procedure report as well as on confirmatory imaging.
- Anatomic landmarks unique to each segment can also help identify the segment being treated.

# Data Issues

When thoracic aorta procedures were mostly performed within the descending thoracic aorta, there was no need to differentiate the segments in the encoded data.

However, that is no longer the clinical environment. Current and on-going surgical advances call for identification of the segment being treated.

- Review of encoded data is enabled by unique values for the different segments.
- Emerging trends in utilization for each segment can be measured with specific body part values.
- Distinctly identifying the segments allows for more clinically meaningful outcome measures and treatment analysis.